



PATIENT Limited exam to locate retained testicle.

Apollo Castaneda **PRESENTING CLINICAL SIGNS**

Rescan N/C for retained testicle

SPECIES **LIMITED ULTRASONOGRAPHIC EXAMINATION OF THE ABDOMEN**

Canine

Retained testicle exhibiting hyperechoic mediastinum testis and mildly enlarged in appearance was present in the mid to caudal abdomen cranial to the urinary bladder and caudal to the right kidney measuring ~ 2.2 cm in diameter. The retained testicle exhibited a non-homogenous, non-capsule deforming nodule measuring 1.2 cm in diameter.

BREED

Belgian Malinois

Sonographically normal urinary bladder.

SEX **ULTRASONOGRAPHIC FINDINGS**

M

Primary

- Retained, mildly enlarged to subjective nodular retained testicle in the mid to caudal abdomen subjective between the right kidney and cranial urinary bladder.

AGE

5yr

INTERPRETATION OF THE FINDINGS & FURTHER RECOMMENDATIONS

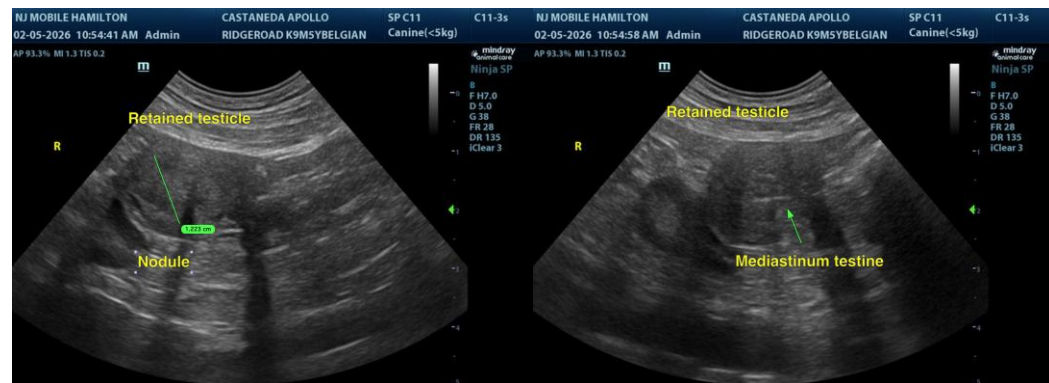
WEIGHT

77lb

Exploratory laparotomy with resection of retained testicle and submission for histopathology is recommended.

INTERPRETED BY

R. McKenzie Daniel,
DVM, DABVP
(Canine and Feline)



IMAGING PERFORMED BY

Rebecca Hamilton

HOSPITAL NAME

Ridge Road AH

REFERRING VET

Dr Pathak

The information and recommendations provided are based on the images presented by the referring veterinarian/sonographer. No evaluation can be communicated regarding pathology that was not visible in the image/video clips provided.

INVOICE
23818

Thank you for this referral. If the clinical or image interpretation does not parallel your findings or if I can be of any further assistance, please contact me.

DATE

02/05/2026



PATIENT

Apollo Castaneda

R. McKenzie Daniel, DVM, DABVP (Canine/Feline Practice)
info@sonopath.com

SPECIES

Canine

BREED

Belgian Malinois

SEX

M

AGE

5yr

WEIGHT

77lb

INTERPRETED BY

R. McKenzie Daniel,
DVM, DABVP
(Canine and Feline)

**IMAGING
PERFORMED BY**

Rebecca Hamilton

HOSPITAL NAME

Ridge Road AH

REFERRING VET

Dr Pathak

**INVOICE
23818**

DATE
02/05/2026